

Case Report

Lipoleiomyoma of Uterus in a Post-menopausal Women

Shastry Srikanth, Gadda Anandam, Rachakonda Suhela, Sunkari Naresh Babu

Department of Pathology, Prathima Institute of Medical Sciences, Karimnagar, Andhra Pradesh, India

ABSTRACT

Lipoleiomyomas are uncommon benign neoplasms of uterus and are considered to be a variant of uterine myomas. Their reported incidence varies from 0.03% to 0.2%. Lipoleiomyoma consists of variable proportion of mature lipocytes and smooth muscle cells. These tumors generally occur in asymptomatic obese perimenopausal or menopausal women. We report this case of uterine lipoleiomyoma because of its rarity.

KEY WORDS: Adipose tissue, lipoleiomyoma, smooth muscle

INTRODUCTION

Lipoleiomyoma is known to be an extremely rare benign tumor of uterus and is suspected to be a variant of leiomyoma. Apart from uterus, it can also occur in different locations including cervix and ovaries. The typical signs and symptoms of lipoleiomyoma are quite similar to that of leiomyoma. It consists of smooth muscles and mature adipose tissue.^[1] Leiomyomas of the uterus are extremely common neoplasms. The overall incidence is between 4% and 11%, but it rises to nearly 40% in women over the age of 50 years. Clinically apparent lesions are less common in parous than nulliparous women and premenopausal than postmenopausal women. They are known to shrink after menopause; this is associated both with fibrosis and with a reduction in the size of the individual tumour cells.

CASE REPORT

A 50-year-old postmenopausal woman presented with increased frequency of per vaginal bleeding since 6 months and distension of abdomen since 15 days. She attained menopause 2 years back. Gynecological examination revealed no specific abnormalities, findings of ultrasonography examination suggested bulky uterus with thickened endometrium of 6 mm and hyperechoic mass suggestive of myoma of posterior wall of uterus,

measuring 3.5 cm in diameter. In addition, transvaginal sonography revealed hyperechoic lesion of 3.5×3.5 cm in the posterofundal region. Also, there were two small subserosal leiomyomas of 0.5 cm diameter each. Both the ovaries showed follicular cysts measuring 3.3×3.3 cm each and tubes were normal in appearance. All the standard serological and hematological parameters were within normal range. The patient underwent total abdominal hysterectomy with bilateral salpingo-oophorectomy because of multiple leiomyomas.

On gross examination of the specimen, the uterus measured $8.5 \times 6.1 \times 5$ cm and had three intramural and subserosal well-circumscribed round masses. The biggest nodule which was measuring 3.5 cm in diameter differed from a typical appearance of uterine leiomyoma by being pale yellow and having a somewhat softer consistency on its cut surface. The other two leiomyomas, each of 0.5 cm diameter showed a coarsely whorled pattern with greyish white appearance on their cut surface. The serosal surfaces of the uterus were normal. Cut-section of ovaries showed follicular cysts of 3.5 cm diameter each. The fallopian tubes appeared grossly normal. Histological examination of the biggest nodule showed a mixture of bland, spindle-shaped smooth muscle cells without nuclear atypia in a whorled pattern with admixed mature adipocytes [Figures 1 and 2]. The adipose component was entirely mature without any lipoblasts. Based on the above findings, the tumor was diagnosed as a benign lipoleiomyoma. Sections from the other fibroids showed classical histomorphology of conventional uterine leiomyomata. The

Access this article online

Quick Response Code



Website:
www.jbcrs.org

DOI:
10.4103/2278-960X.129285

Address for correspondence

Dr. S Srikanth,
Department of Pathology, Prathima Institute of Medical Sciences,
Karimnagar, Andhra Pradesh, India.
E-mail: drshastrysri@yahoo.com

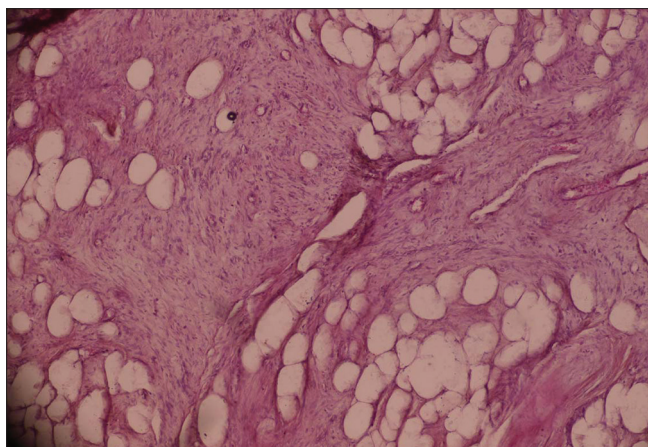


Figure 1: Mature adipocytes within leiomyoma (H and E, ×40)

endometrium showed changes of simple hyperplasia without atypia. Sections from both the ovaries showed follicular cysts with the tubes being unremarkable histologically.

DISCUSSION

Benign lipoleiomyomatous uterine tumours are rare and their histologic spectrum includes pure lipomas, lipoleiomyomas and fibromyolipomas.^[2] The incidence of lipoleiomyoma varies between 0.03% and 0.2%. Majority of the patients are post-menopausal predominantly in their 50's and 60's.^[2] They present with clinical symptoms similar to that of ordinary leiomyomas.^[3] Uterine lipoleiomyomas are most frequently found in the uterine corpus and are unusually intramural but can found anywhere in the uterus or cervix and can also be subserosal in location.^[4] Many variants which are the result of secondary changes have been described and are detectable in around 65% of cases. Lipoleiomyoma is an alteration that was previously called as fatty metamorphosis, lipomatous degeneration, adipose metaplasia, etc. It is now regarded as a distinct true neoplasm.

It is prevalent in peri-menopausal women, often associated with multiple leiomyomas with a preference in sub-serosa. Pathogenesis has been variously ascribed to as mixed, benign, heterologous or mesenchymal neoplasm.^[5] The lesion is benign and the only puzzle for the pathologist could be the unexpected presence of fat in a uterine tumor.^[6] Diagnosis of pure lipoma is made when any smooth muscle,

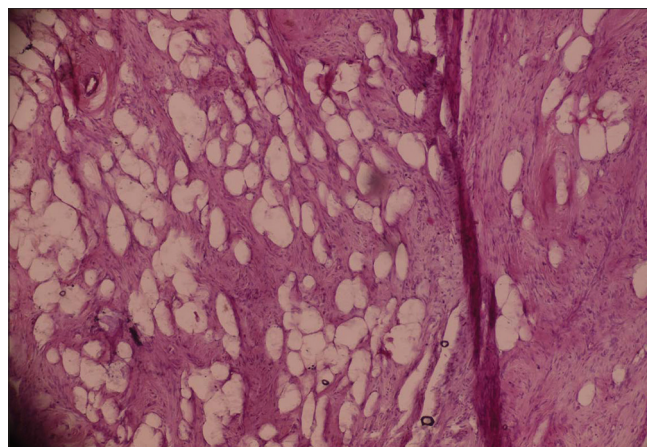


Figure 2: Smooth muscle tissue arranged in whorls and in fascicles with mature adipose tissue (H and E, ×40)

if present, is confined to periphery of the tumor.

Lipoleiomyomas when asymptomatic require no treatment and are clinically similar to leiomyomas. Furthermore, it is important to differentiate these tumors from ovarian teratoma, which requires surgical excision. Though imaging plays an important role in preoperative diagnosis and localization of the lipoleiomyoma, it is the final pathological examination that confirms the diagnosis. We present this case because of its rarity.

REFERENCES

1. Dharkar DD, Kraft JR, Gangadharam D. Uterine lipomas. Arch Pathol Lab Med 1981;105:43-5.
2. Houser LM, Carrasco CH, Sheehan CR Jr. Lipomatous tumour of the uterus: Radiographic and ultrasonic appearance. Br J Radiol 1979;52:992-3.
3. Oppenheimer DA, Carroll BA, Young SW. Lipoleiomyoma of the uterus. J Comput Assist Tomogr 1982;6:640-2.
4. Aizenstein R, Wilbur AC, Aizenstein S. CT and MRI of uterine lipoleiomyoma. Gynecol Oncol 1991;40:274-6.
5. Dey P, Dhar KK. Lipomatous tumour of uterus. J Indian Med Assoc 1993;91:99.
6. Hendrikson MR, Longacre AT, Kempson RL. The uterine corpus. In: Mills SE, editor. Sternberg's Diagnostic Surgical Pathology. 4th ed. Philadelphia: Lippincott Williams and Wilkins; 2004. p. 2519.

How to cite this article: Srikanth S, Anandam G, Suhela R, Babu SN. Lipoleiomyoma of uterus in a post-menopausal women. J Basic Clin Reprod Sci 2014;3:62-3.

Source of Support: Nil, **Conflict of Interest:** None declared

JOURNAL OF BASIC and CLINICAL REPRODUCTIVE SCIENCES

Official Publication of Society of Reproductive Biologist of Nigeria

Volume 1 / Issue 1 / Year 2012

www.jbcrs.org

