

Case Report

Filariasis in Pregnancy: Prevalent yet Less-known Global Health Burden

Garugubilli Chandrakala, Momina Zulfeen

Department of Obstetrics and Gynecology, Siddhartha Medical College, Vijayawada, Andhra Pradesh, India

ABSTRACT

Parasitic infections affect tens of millions of pregnant women worldwide. Lymphatic filariasis is a vector-borne disabling parasitic infection and is an endemic disease in many parts of Southeast Asia, especially South India, with most infections caused by *Wuchereria bancrofti*. The aim of this article is to present a rare case of incidental filariasis in pregnancy with unexpected outcome. We report a normotensive 45-year-old multigravida with 7 months gestation, moderate anemia, fever, inguinal lymphadenopathy, and elephantiasis. Her peripheral smears were positive for microfilaria while ultrasound revealed intrauterine fetal death and chronic abruption. She was negative on risk factors for abruption, except for advanced maternal age. This case warrants more global attention to the management of parasitic infection in pregnancy.

KEY WORDS: Abruption, elephantiasis, filariasis, fetal death, lymphadenopathy, parasitic infection

INTRODUCTION

Lymphatic filariasis is a vector-borne disabling parasitic infection causing elephantiasis, lymphedema, and hydrocele (in males). The infection is endemic in 83 countries worldwide, with more than 1.2 billion people at risk and 120 million already infected. It is an endemic disease in many parts of Southeast Asia, especially South India.^[1] The statistics in pregnant women are poorly known due to the exclusion of pregnant women from filarial mass treatment strategies.^[2] Without further investigations, filariasis in pregnancy remains a neglected tropical disease.^[3] This case of filariasis in pregnancy is a reflection of this global burden.

CASE REPORT

This rare case of inguinal lymphangioarix and chronic abruption in pregnancy is of a 45-year-old gravida 3 para 2 and live 2 woman with 7 months amenorrhea presenting with complaints of painful swelling in both the inguinal regions and with history of low-grade, periodic fever lasting for 4–5 days every month. On examination, she was febrile with 101°F and anemic. There was a soft, nodular,

mobile, tender mass of about 3 cm in the right inguinal region and similar mass of 2 cm in the left inguinal region. There was no other swelling or lymph node enlargement anywhere else and was not associated with organomegaly. There was nonpitting edema in both the limbs and pitting edema in the left arm [Figure 1]. The skin over edema was dry and there was no rubor, calor, or dolor. General physical examination was otherwise normal. Her vitals were normal with blood pressure of 130/80 and pulse rate of 88/min. Her obstetric examination corresponded with gestational age and fetal heart sounds were not audible on auscultation. Her ultrasound was suggestive of an intrauterine death and chronic abruption. She was managed accordingly.

Investigations

Her blood investigations were significant for hemoglobin 7 g %, raised erythrocyte sedimentation rate of 40 mm, and total count of 12,000 with lymphocytosis. Peripheral smear

Address for correspondence

Dr. Momina Zulfeen,
H. No. 3-7-213, Nalanda Nagar, AG Colony, Attapur,
Hyderabad, Telangana, India.
E-mail: mominazulfeen@gmail.com

Access this article online

Quick Response Code



Website:

www.jbcrs.org

DOI:

10.4103/2278-960X.194484

This is an open access article distributed under the terms of the Creative Commons Attribution-NonCommercial-ShareAlike 3.0 License, which allows others to remix, tweak, and build upon the work non-commercially, as long as the author is credited and the new creations are licensed under the identical terms.

For reprints contact: reprints@medknow.com

How to cite this article: Chandrakala G, Zulfeen M. Filariasis in pregnancy: Prevalent yet less-known global health burden. *J Basic Clin Reprod Sci* 2016;5:107-9.

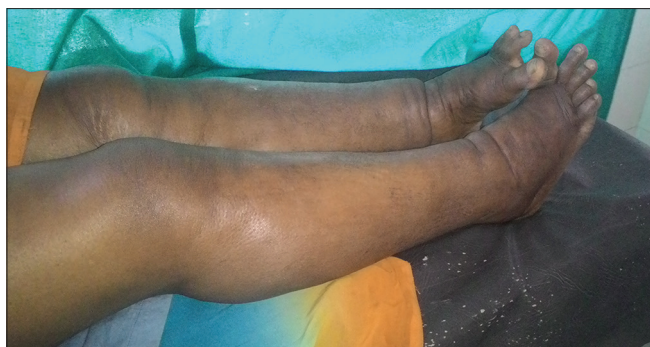

Figure 1: Bilateral nonpitting pedal edema

showed numerous microfilariae in a background microcytic hypochromic red blood cell and few lymphocytes. Since the patient was pregnant, diethylcarbamazine (DEC) was not advised.

Treatment

She delivered a fresh stillbirth with early growth retardation 6 h after induction of labor and 400 g of retroplacental clots was observed. She was then put on DEC and managed medically. She was discharged healthy and follow-up was done. Histopathology of placental tissue was confirmatory for chronic abruption and was negative on pathogens. There was no evidence of inflammation.

DISCUSSION

Filariasis is a well-known endemic disease in developing countries,^[1] but its incidence in pregnancy and its impact on the fetus are less-investigated areas in medicine.^[3,4] This blood-borne parasite leads to local inflammation with lymph node involvement, including in the pelvis, and possibly affecting reproductive organs. Filariasis has acute and chronic phases.^[5] The acute phase is caused by microfilaremia and is associated with relapsing fever, skin inflammation, and malaise. However, it is the chronic phase that causes significant morbidity. The parasite migrates toward the vessels in legs and pelvis, causing severe lymph varices and elephantiasis over time.^[6] Filariasis is diagnosed by microscopic visualization of parasites from blood or tissue samples.^[7]

Evidence for the transplacental transfer of filarial parasites has come from studies on *Dirofilaria immitis* in dogs (Mantovani, 1966; Todd and Howland, 1983) and *Brugia pahangi* (Sucharit and Rongsriyam, 1980) and *Dipetalonema viteae* (Haque *et al.*, 1988) in rats. The frequency with which the transplacental passage of *Wuchereria bancrofti* microfilariae, from infected women to their fetuses, occurs during normal pregnancies remains a controversial issue (Weil *et al.*, 1983). Microfilariae are rarely detected in samples of human cord blood, even those from microfilaremic mothers, but this may

be attributable, at least in part, to the low sensitivity of the detection tests employed (Weil *et al.*, 1983). Most children born to mothers with circulating filarial antigen become antigenemic themselves while *in utero*, and it is probably the transplacental transfer of filarial antigens, rather than transplacental infection that sensitizes many fetuses to filarial infection. Maternal antigenemia can potentially increase an infant or child's susceptibility to filarial infection – possibly producing a state of immunological tolerance in the unborn fetus (Lammie *et al.*, 1991). Environmental control and rapid impact packages for mass antihelminthic drug administration are staples of the helminth infection eradication effort.^[3]

In the past, antihelminthic medications were avoided in pregnancy and lactating women out of safety concerns for the fetus.^[8] In areas where helminth infections are endemic, treatment regimens are delayed for years because many women are pregnant and breastfeeding for more than half of their reproductive lives. This delay has led to significant morbidity in mother and their infants.

Similar to other helminthic infections, lymphatic filariasis has been shown to have prominent symptoms in pregnancy affecting both the mother and the developing fetus.^[9] Although filariasis usually is an incidental finding in pregnancy,^[2] its impact on the fetus is less known. Chronic infection leads to distortion of anatomy as well as secondary bacterial infections. This can be socially devastating for the mother.^[6] Furthermore, it has been postulated that infants born to mothers with filariasis during pregnancy can have hyporesponsiveness to infections in the future as infant or child.^[4] This patient here is an elderly gravida with chronic anemia and chronic abruption along with active filarial infection; she was otherwise normotensive. The cause of abruption in this case could not be attributed to any obvious cause and filarial infection itself as a cause could not be ruled out due to lack of insufficient data. Little is known about additional helminth infections in pregnancy or its association with filariasis.^[10] However, each organism has potentially devastating outcomes on the mother and the developing fetus. Given this potential, helminth infection during pregnancy warrant, further investigation as the global impact could be massive.

CONCLUSION

Parasitic infections in pregnancy directly or indirectly lead to a spectrum of adverse maternal or fetal outcomes and placental effects. Their consequences in chronically undernourished anemic women of reproductive age are considerable. More global attention to the diagnosis and treatment of parasitic infections in pregnancy are warranted. There is not enough

research on treatment modalities in filariasis in pregnancy. DEC being contraindicated in pregnancy is a limitation. This is why our case is unique and gives an insight into the possible global impact of the condition, warranting the need to implement screening techniques, mass prevention, and new antihelminthic drug trials in pregnancy.

Financial support and sponsorship


Nil.

Conflicts of interest

There are no conflicts of interest.

REFERENCES

1. World Health Organisation. Parasitic Disease. Available from: <http://www.who.int/ivr>. [Last retrieved on 2012 Jan 05].
2. Shaw S, Pegrum GD. Filariasis as an incidental finding in pregnancy. *Postgrad Med J* 1965;41:27-9.
3. Weerasinghe CR, de Silva NR, Michael E. Maternal filarial infection status and its consequences on pregnancy and the newborn, in Ragama, Sri Lanka. *Ann Trop Med Parasitol* 2005;99:813-6.
4. Elliott AM, Ndibazza J, Mpairwe H, Muhangi L, Webb EL, Kizito D, et al. Treatment with anthelmintics during pregnancy: What gains and what risks for the mother and child? *Parasitology* 2011;138:1499-507.
5. Bal MS, Mandal NN, DAS MK, Kar SK, Sarangi SS, Beuria MK. Transplacental transfer of filarial antigens from *Wuchereria bancrofti*-infected mothers to their offspring. *Parasitology* 2010;137:669-73.
6. Shenoy RK. Clinical and pathological aspects of filarial lymphedema and its management. *Korean J Parasitol* 2008;46:119-25.
7. Bockarie MJ, Taylor MJ, Gyapong JO. Current practices in the management of lymphatic filariasis. *Expert Rev Anti Infect Ther* 2009;7:595-605.
8. Haider BA, Humayun Q, Bhutta ZA. Effect of administration of anthelmintics for soil transmitted helminths during pregnancy. *Cochrane Database Syst Rev* 2009;(2):CD005547.
9. Petersen E. Protozoan and helminth infections in pregnancy. Short-term and long-term implications of transmission of infection from mother to foetus. *Parasitology* 2007;134(Pt 13):1855-62.
10. Hotez PJ, Brindley PJ, Bethony JM, King CH, Pearce EJ, Jacobson J. Helminth infections: The great neglected tropical diseases. *J Clin Invest* 2008;118:1311-21.



JOURNAL OF BASIC and CLINICAL REPRODUCTIVE SCIENCES

Official Publication of Society of Reproductive Biologist of Nigeria

Volume 1 / Issue 1 / Year 2012

www.jbcrs.org

J B C R S