

## Case Report

# Aspergillus Salpingitis: A Rare Case Report

Vidula Prashant Gowardhan, Anne R. Wilkinson, Sadhana D. Mahore, Radhika Mhatre

Department of Pathology, NKPSIMS, Nagpur, Maharashtra, India

### ABSTRACT

We describe the pathology of a unique case of fallopian tube aspergillosis in a 45 year old woman. She complained of lower abdominal pain and lump in lower abdomen since 2-3 months. Clinically she was diagnosed as benign ovarian tumor, right ovary. Pathological examination showed dilated fallopian tube containing yellow material. Microscopic examination showed Aspergillous filaments surrounded by dense infiltrate of neutrophils and lymphocytes. Even though Aspergillous salpingitis is a rare entity, the correct diagnosis is of great importance for the indication of proper therapy.

**KEY WORDS:** Aspergillus, aspergillosis, salpingitis

### INTRODUCTION

Salpingitis is the most common serious infection in women of reproductive age. It is believed to be an ascending infection that results from the direct spread of organisms from the endocervix to the endometrium and then the fallopian tube mucosa. The clinical presentation of salpingitis is highly diverse, ranging from asymptomatic to severe pelvic pain to diffuse peritonitis to, rarely, life-threatening illness. Granulomatous salpingitis can be caused by various kinds of organisms; of which fungi, especially aspergilli are very rare.

### CASE REPORT

A 45-year-old woman, P<sub>3</sub>L<sub>3</sub> presented with lump, pain in abdomen, and amenorrhea since 4 months. Clinically, a large mass of size 15 cm × 10 cm was palpated in the lower abdomen, right side, and on per vaginum examination. Past history was not significant. Hence a provisional clinical diagnosis of adnexal tumor was kept. The laboratory tests such as hemogram, liver function test, kidney function test, as well as CA 125 showed normal results.

Abdominal USG revealed a mass likely originating from right ovary.

The patient underwent a total abdominal hysterectomy with right salpingo-oophorectomy.

### Pathological findings

#### Gross

Specimen of the uterus with cervix with right salpingo-oophorectomy was received. The right fallopian tube was dilated (measuring 6 cm × 4 cm) and contained yellow material in the lumen [Figure 1]. Ovary showed a cyst measuring 1.5 cm × 0.5 cm.

#### Microscopy

The fallopian tube showed a dilated lumen of the tube and fused plicae. The lumen contained fungal filaments surrounded by dense inflammation in the wall. Thin septate hyphae with acute angle branching were diagnosed as those

#### Address for correspondence:

Dr. Vidula Prashant Gowardhan,  
28, Friend's Layout 4,  
Dindayal Nagar, Nagpur, Maharashtra, India.  
E-mail: v\_gowardhan@rediffmail.com

#### Access this article online

##### Quick Response Code



##### Website:

[www.jbcrs.org](http://www.jbcrs.org)

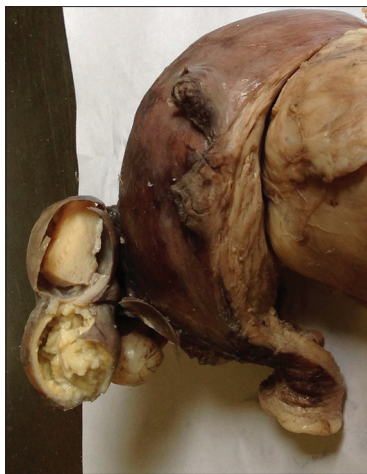##### DOI:

10.4103/2278-960X.161064

This is an open access article distributed under the terms of the Creative Commons Attribution-NonCommercial-ShareAlike 3.0 License, which allows others to remix, tweak, and build upon the work non-commercially, as long as the author is credited and the new creations are licensed under the identical terms.

**For reprints contact:** [reprints@medknow.com](mailto:reprints@medknow.com)

**How to cite this article:** Gowardhan VP, Wilkinson AR, Mahore SD, Mhatre R. Aspergillus salpingitis: A rare case report. J Basic Clin Reprod Sci 2015;4:97-9.



**Figure 1:** Photograph of uterus with cervix and dilated right fallopian tube containing yellow material

of *Aspergillus* species [Figure 2]. There was follicular cyst in the ovary.

## DISCUSSION

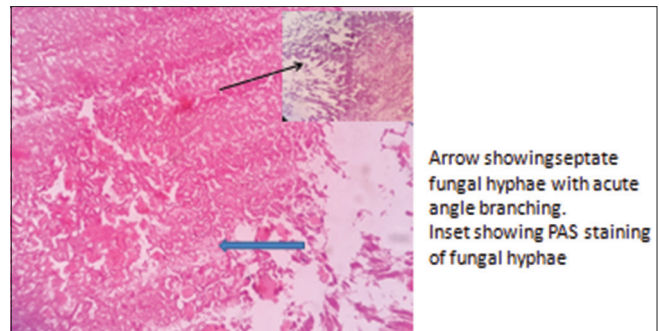
Acute salpingitis is a spontaneous infection that occurs among sexually active, menstruating, nonpregnant women. The majority of infections are caused by bacteria, and a polymicrobial bacterial infection is common. *Neisseria gonorrhoeae*, *Chlamydia trachomatis*, and a wide variety of aerobic and anaerobic bacteria are most frequently isolated from women with acute salpingitis. Genital mycoplasmas also have been recovered from a small number of infections. A tuberculous, parasitic or fungal salpingitis is rare among women in industrialized countries.

Salpingitis occurs in an estimated 15% of reproductive-age women, and 2.5% of all women become infertile as a result of salpingitis by age 35.<sup>[1]</sup>

Acute salpingitis with or without oophoritis often coexists with various degrees of pelvic peritonitis. The infertility results from tubal occlusion, peritubal adhesions, or adhesions encasing the ovary in any combination.

Salpingitis is usually bilateral, but an 8% incidence of the unilateral disease is reported; this manifestation may be more common in women using intrauterine devices.<sup>[2]</sup> Prompt recognition and vigorous treatment reduces subsequent severe complications of salpingo-oophoritis such as generalized pelvic peritonitis, abscess formation, and adnexal destruction. It deserves reemphasis that salpingitis often produces minimal clinical signs.

The genital tract infections spread by (a) direct extension along luminal surfaces which are characteristic of gonococcal and



**Figure 2:** Photomicrograph showing acute angle branching of septate fungal hyphae. Inset showing periodic acid-Schiff positive fungal hyphae

chlamydial infection (b) Through lymphatics and blood vessels (nongonococcal bacterial and genital mycoplasma infections).

Fungi are rare causes of granulomatous salpingitis, with cases of blastomycosis, and more commonly coccidioidomycosis being reported in the American literature.<sup>[3]</sup>

The overall prevalence of fungal infection has shown a rising trend in the last two decades. Similar reports have been published from India earlier, and this is attributed to variability of climatic conditions of this country. The newer chemotherapeutic and antibiotic modalities, transplant facilities, stay in critical care units, are additional factors that contribute to the overall increase in the incidence of fungal infection.<sup>[4]</sup>

In our case, the fungal infection was not suspected clinically so fungal culture could not be done on the specimen received in formalin. Many studies also reported that fungal infections are frequently missed clinically and often diagnosed only at autopsy.<sup>[5]</sup>

*Aspergilli* are very common and frequently occur in compost heaps, air vents, and airborne dust. Inhalation of *Aspergillus* spores is the primary cause of aspergillosis. Aspergillosis has several forms: Pulmonary aspergilloma, invasive aspergillosis: Allergic bronchopulmonary aspergillosis.

It is common for spores of *Aspergillus* to enter our bodies continuously through the respiratory system, at rates of hundreds per day without creating any complications in healthy individuals. However, those individuals with compromised immune systems, especially those recipients of stem-cell and solid organ transplants, those undergoing chemotherapy and those with advanced HIV infection, are particularly at risk in developing the disease when exposed to the fungus.<sup>[6]</sup>

A case of aspergillosis in a broiler breeder flock having respiratory and nervous system problems caused by *Aspergillus fumigatus* and *Aspergillus niger* is documented.<sup>[7]</sup>

Even though it is a rare disease, the correct diagnosis is of paramount importance for the indication of proper therapy.

### Financial support and sponsorship


Nil.

### Conflicts of interest

There are no conflicts of interest.

## REFERENCES

1. Weström LV. Sexually transmitted diseases and infertility. *Sex Transm Dis* 1994;21 2 Suppl: S32-7.
2. Sweet RL: Diagnosis and treatment of acute salpingitis. *J Reprod Med* 19:21-30,1977. Novy M, Eschenbach D, *et al*, *Glob. Libr. Women's Med*; (ISSN:1756-2228) 2008;DOI 10.3843/GLOWM.10328.
3. Sternberg. *The Fallopian tube and broad ligament. Sternberg's Diagnostic Surgical Pathology*. 5<sup>th</sup> ed., Vol. II, Ch. 57. Lippincot Williams and Wilkins. September 2009:2375
4. Uppin MS, Anuradha SV, Uppin SG, Paul TR, Prayaga AK, Sundaram C. Fungal infections as a contributing cause of death: An autopsy study. *Indian J Pathol Microbiol* 2011;54:344-9.
5. Sarode VR, Datta BN, Banerjee AK, Banerjee CK, Joshi K, Bhusnurmath B, *et al*. Autopsy findings and clinical diagnoses: A review of 1,000 cases. *Hum Pathol* 1993;24:194-8.
6. Aspergillosis: Fernando A. Fernandez, *Environmental Reporter*; Vol. 8, Issue 7. A case of Aspergillosis in a Broiler Breeder Flock. *Avian Diseases* 2002;46:497-501.
7. Akan M, Haziroglu R, Ilhan Z, Sareyyüpoğlu B, Tunca R. A case of aspergillosis in a broiler breeder flock. *Avian Dis* 2002;46:497-501.



# JOURNAL OF BASIC and CLINICAL REPRODUCTIVE SCIENCES

Official Publication of Society of Reproductive Biologist of Nigeria

Volume 1 / Issue 1 / Year 2012

[www.jbcrs.org](http://www.jbcrs.org)

J B C R S

