

Accuracy of Gray-scale and Three-dimensional Power Doppler Ultrasound Parameters in the Diagnosis of Morbidly Adherent Placenta

Alaa M. Abdel Moniem, Ibrahim A. Abdelazim^{1,2}, Amr A. Aziz Khalifa¹, Ahmed A. Kader Fahmy¹, Noha H. Rabei¹

Departments of Ultrasound and Fetal Care Unit and ¹Obstetrics and Gynecology, Ain Shams University, Cairo, Egypt, ²Department of Obstetrics and Gynecology, Ahmadi Kuwait Oil Company Hospital, Ahmadi, Kuwait

ABSTRACT

Background: Morbidly adherent placenta (MAP) is usually associated with excess blood loss, bladder injuries, and hysterectomies. **Aim:** This study was designed to evaluate the accuracy of grayscale and three-dimensional (3D) power Doppler ultrasound parameters in the diagnosis of MAP. **Subjects and Methods:** Fifty pregnant women ≥ 28 weeks' gestation with suspected MAP were included randomly in this prospective study. Two-dimensional (2D) transabdominal gray-scale ultrasound and 3D power Doppler scans were done for studied women to confirm placental location and findings suggestive of MAP. Intraoperative findings and histopathology results of removed uteri in the cases were managed by hysterectomies compared to preoperative sonographic findings using Student's t-test and Mann-Whitney U-test for quantitative data, Chi-square test for qualitative data to detect the accuracy of 2D transabdominal gray-scale ultrasound and 3D power Doppler parameters in the diagnosis of MAP. **Results:** Best 2D gray scale ultrasound parameters for the detection of emergency hysterectomies in the studied cases were disruption of uterine serosa-bladder interface (81.8% sensitivity) and exophytic mass invading bladder (94.9% specificity, 66.7% positive predictive value (PPV), and 84.1% negative predictive value [NPV]). Best 3D power Doppler parameters for the detection of emergency hysterectomies in the studied cases were disruption of uterine serosa-bladder interface (90.9% sensitivity, 68.8% specificity, and 47% PPV) and crowded vessels over peripheral subplacental zone (93.2% NPV). **Conclusion:** 3D power Doppler is a useful complementary tool to 2D gray-scale ultrasound for antenatal diagnosis of MAP. Crowded vessels over peripheral sub-placental zone and disruption of uterine serosa-bladder interface were the best 3D power Doppler parameters for the detection of difficult placental separation, considerable intraoperative blood loss, and emergency hysterectomies in the studied cases.

KEY WORDS: Three-dimensional power Doppler, gray-scale, morbidly adherent placenta

INTRODUCTION

Placenta accreta occurs when placental trophoblasts invade endometrium beyond the Nitabuch's layer of decidua basalis, while placenta increta occurs when placental trophoblasts invade myometrium, and placenta percreta occurs when trophoblasts invade myometrium deep to reach serosal covering of the uterus.^[1,2]

Morbidly adherent placenta (MAP) is usually associated with excess blood loss, bladder injuries, and hysterectomies.^[3,4]

The incidence of MAP has increased significantly over the last 50 years.^[5,6] Previous cesarean delivery, placenta previa,

and damage of Nitabuch's layer of decidua basalis following intrauterine infection or intrauterine scarring are the risk factors of MAP.^[1,7-9]

The incidence of MAP is increased concomitantly with increased cesarean section rates.^[1,7-9] The incidence of MAP is 3.3% in pregnant women with no prior cesarean delivery and placenta previa and 40% in pregnant women

Address for correspondence

Prof. Ibrahim A. Abdelazim,
Ahmadi Hospital, Kuwait Oil Company, P.O. Box 9758,
Ahmadi 61008, Kuwait.
E-mail: dr.ibrahimanwar@gmail.com

Access this article online

Quick Response Code



Website:

www.jbcrs.org

DOI:

10.4103/2278-960X.175738

This is an open access article distributed under the terms of the Creative Commons Attribution-NonCommercial-ShareAlike 3.0 License, which allows others to remix, tweak, and build upon the work non-commercially, as long as the author is credited and the new creations are licensed under the identical terms.

For reprints contact: reprints@medknow.com

How to cite this article: Abdel Moniem AM, Abdelazim IA, Aziz Khalifa AA, Kader Fahmy AA, Rabei NH. Accuracy of gray-scale and three-dimensional power doppler ultrasound parameters in the diagnosis of morbidly adherent placenta. J Basic Clin Reprod Sci 2016;5:12-20.

with previous two cesarean sections and placenta previa.^[4]

If MAP was diagnosed or suspected before delivery, the optimum time for planned delivery is around 34–35 weeks following a course of corticosteroid and multidisciplinary care team approach.^[2,10,11]

Accurate diagnosis of MAP is essential to prepare both patient and health providers for possible complications. Authors reported that ultrasound is a useful tool to diagnose MAP with 77–93% sensitivity and 71–98% specificity.^[12–16]

Moodley *et al.* concluded that color flow Doppler was more specific in the diagnosis of MAP with 95% negative predictive value (NPV) than magnetic resonance imaging (MRI).^[17]

Prenatal diagnosis of MAP with gray-scale and Doppler sonography allows development of multidisciplinary care team approach during delivery.^[14]

The diagnosis of MAP is possible using gray-scale sonography, color Doppler imaging, and MRI through studying the relation of placenta to the uterine wall. The new modality of three-dimensional (3D) and 3D color power Doppler ultrasound has the potential for providing additional information and diagnostic accuracy of MAP over two-dimensional (2D) ultrasound by assessing the extent, location, and quantification of abnormal uteroplacental neovascularization.^[18]

This study was designed to evaluate the accuracy of gray-scale and 3D power Doppler ultrasound parameters in the diagnosis of MAP.

SUBJECTS AND METHODS

From February 2011 to February 2013, pregnant women ≥ 28 weeks' gestation with placenta previa anterior covering scar of previous cesarean section and scar by trans-abdominal gray-scale ultrasound scan were randomly included in this study after the approval of local Institute Ethical Committee of Ain Shams Maternity University Hospital and after obtaining informed consent.

A written consent was taken from all studied women (two women refused to participate in this study) explaining possible intraoperative complications (blood transfusion, hysterectomy, and internal iliac ligation) and postoperative complications (deep venous thrombosis, prolonged hospital stay, and Intensive Care Unit admission).

Thorough history and examination of all studied women followed by 2D trans-abdominal gray-scale ultrasound scan

to confirm gestational age, placental location, and findings suggestive of MAP. Findings suggestive of MAP by 2D gray-scale ultrasound scan were:

1. Obliteration of clear space between uterus and placenta [Figure 1b]
2. Visualization of placental lacunae (irregular vascular spaces), moth-eaten appearance placenta [Figure 1]
3. Interruption of posterior uterine serosa–bladder interface
4. Exophytic mass invading bladder.^[11,19]

2D gray-scale ultrasound scan followed by 3D power Doppler by sonographer blinded to patients' criteria was used to confirm the diagnosis of MAP. All scans were done for all studied women in the supine position with sufficient and comfortable bladder volume to allow optimal visualization of uterine serosa–bladder interface using Medison machine (SonoAce X⁸, Medison Co, South Korea) with 4–7 Mhz (Megahertz) multi-frequency convex probe.

3D power Doppler was targeted to analyze and define the vasculature of lower uterine segment and placenta (region of interest [ROI]). Using curved array transducer with 100% power, 0.9 KHz pulse repetition frequency, 3D power Doppler done and three to five 3D volumes were obtained. 3D power Doppler images were analyzed using virtual organ computer-aided analysis (VOCAL). Two views of 3D power Doppler were usually analyzed; lateral view to observe intra-placental vasculature and basal view to observe serosa–bladder interface. At least, one of the following findings was suggestive of MAP by 3D power Doppler when ROI was examined:

1. Disruption of retroplacental sonolucent zone and/or abnormal placental lacunae in lateral view
2. Numerous vessels invading serosa–bladder interface and/or crowded vessels over the peripheral sub-placental zone in basal view [Figure 2].

According to hospital protocol, studied women were hospitalized at 32 weeks and delivered at 35 weeks, following a course of corticosteroids.

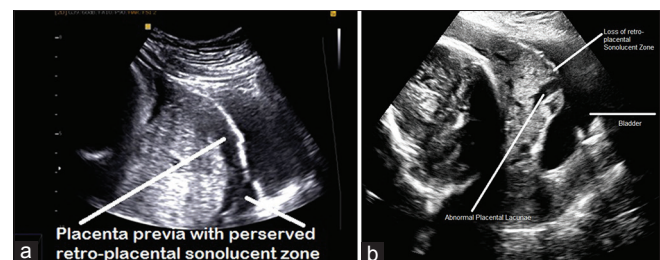


Figure 1: (a) Placenta previa with preserved retro-placental sonolucent zone and no abnormal placental. (b) Two-dimensional gray-scale ultrasound scan of morbidly adherent placenta with loss of retroplacental sonolucent zone and abnormal placental

Emergency cesarean was done in the case of significant bleeding before the time of planned delivery. All deliveries conducted in the attendance of obstetrics and anesthetic consultants on duty and urologist on duty were informed in the case of bladder injuries.^[2-10]

Women included in this study were also cross matched with fresh frozen plasma and packed red blood cells.

Intraoperative findings including difficulty in placental separation, degree of placental invasion, bleeding from placental site, amount of blood loss, intraoperative blood transfusion, need for internal iliac ligation or emergency hysterectomies to control bleeding, and histopathology results of removed uteri in the cases managed by emergency hysterectomies were recorded.^[20]

Calculated estimated blood loss was evaluated using Stafford *et al*'s formula.^[21]

Intraoperative findings were compared with preoperative sonographic findings to detect the accuracy of 2D trans-abdominal gray-scale ultrasound and 3D power Doppler parameters in the diagnosis of MAP.

Sample size justification and statistical analysis

Using data from previous studies^[3] and EpiInfo[®] Version 3.5.1 (CDC, Atlanta, Georgia, USA), setting the power at 80%, two-sided confidence interval at 95%, a sample size of 50 women was needed to produce a significant difference. Data were collected and statistically analyzed using SPSS (Statistical Package for Social Sciences); computer software version 18 (IBM Corporation, Chicago, IL, USA). Mean and standard deviation were used to represent numerical variables, whereas number and percentage were used to represent categorical variables. Student's *t*-test and Mann–Whitney U test were used for the analysis of quantitative data, Chi-square test for the analysis of qualitative data, and regression analysis to predict the outcome of categorical dependent variables.

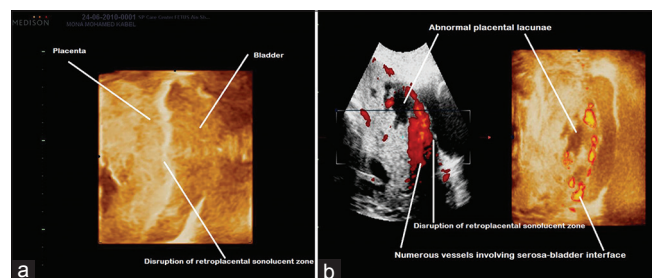


Figure 2: (a) Three-dimensional ultrasound of morbidly adherent placenta with disruption of retroplacental sonolucency. (b) Three-dimensional power Doppler of morbidly adherent placenta with numerous vessels involving serosa–bladder interface, disruption of retroplacental sonolucency, and abnormal placenta

$P < 0.05$ was considered significant. Also, sensitivity, specificity, and predictive values of ultrasound diagnostic criteria of MAP were calculated.

RESULTS

Demographic data of 50 studied women with suspected MAP are represented in Table 1.

Fifty-six percentage (28/50) of studied women had difficulty in placental separation, considerable blood loss (≥ 1500 CC), and received blood transfusion. Bilateral internal iliac artery ligation was done to control bleeding in 28% (14/50) of studied women, intrauterine compression balloon with placenta bed sutures was done in 6% (3/50) of studied women, and cesarean hysterectomies were done in 22% (11/50) of studied women. Histopathological examination of surgically removed uteri showed placenta accreta in 10% (5/50) cases, placenta increta in 8% (4/50) cases, and placenta percreta in 4% (2/50) cases.

Ten percentage (5/50) cases of bladder injuries were recorded during this study [Table 1].

Number of cesarean deliveries and parity were high among women, who had difficulty in placental delivery, who had considerable intraoperative blood loss, and who required emergency hysterectomies to control bleeding [Table 2].

All 2D gray-scale ultrasound and 3D power Doppler parameters (except abnormal placental lacunae) were significantly high in women who had difficulty in placental separation and considerable intraoperative blood loss

Table 1: Preoperative and intraoperative data of studied women with suspected morbid adherent placenta

Variables	Total number of studied women=50 (%)
Age (years)	31.22 (4.82)*
Duration from last cesarean section (years)	3.4 (2.39)*
Gestational age at scan (weeks)	30.6 (3.17)*
Gestational age at delivery (weeks)	34.7 (1.2)*
Preoperative hematocrit	30.8 (3.3)*
48-hour postoperative hematocrit	27.3 (4.1)*
Postoperative hematocrit drop	3.4 (2.4)*
Considerable intraoperative blood loss (≥ 1500 cc)	28 (56)**
Intraoperative blood transfusion	28 (56)**
Easy placental separation	22 (44)**
Difficult placental separation	28 (56)**
No need for additional surgical steps	22 (44)**
Bilateral internal iliac ligation	14 (28)**
Emergency hysterectomy	11 (22)**
Intrauterine compression balloon and placental bed sutures	3 (6)**
Histopathology results of surgically removed uteri	
Placenta accrete	5 (10)**
Placenta increta	4 (8)**
Placenta percreta	2 (4)**
Intraoperative bladder injury	5 (10)**

*Data represented as mean (SD), **Data represented as number and percentage. SD=Standard deviation

compared with women who did not have difficulty in placental separation or considerable blood loss [Table 3].

Regression analysis showed that the risk of difficulty in placental separation and considerable intraoperative blood loss increased 3 times (95% CI; 1.7–8.5) with irregular retro-placental sonolucent areas, 7 times (95% CI; 1.8–27.2) with disruption of uterine serosa–bladder interface, and 13.4 times (95% CI; 0.8–22.1) with exophytic mass invading bladder by 2D gray-scale ultrasound scan.

In addition, regression analysis showed that the risk of difficulty in placental separation and considerable intraoperative blood loss increased 2.8 times (95% CI; 1.4–5.8) with disruption of uterine serosa–bladder interface and numerous vessels invading serosa–bladder interface and 3.2 times (95% CI; 1.6–6.5) with crowded vessels over peripheral sub-placental zone by 3D power Doppler scan [Table 3].

All 2D gray-scale ultrasound parameters except abnormal placental lacunae and all 3D power Doppler parameters except numerous vessels invading serosa–bladder interface

were significantly high in women who required emergency hysterectomies compared with women who did not require hysterectomies [Table 4].

Regression analysis showed that the risk of emergency hysterectomies to control bleeding in studied cases of MAP increased 3.2 times (95% CI; 2–5.2) with irregular retro-placental sonolucent areas, 4.5 times (95% CI; 2.2–9.4) with disruption of uterine serosa–bladder interface, and 7.1 times (95% CI; 1.4–33.7) with exophytic mass invading bladder by 2D gray-scale ultrasound scan [Table 4].

In addition, regression analysis showed that the risk of emergency hysterectomies to control bleeding in studied cases of MAP increased 2.9 times (95% CI; 1.7–4.9) with crowded vessels over peripheral sub-placental zone, 3.2 times (95% CI; 1.8–5.5) with abnormal placental lacunae, and 3.4 times (95% CI; 1.8–6.3) with disruption of uterine serosa–bladder interface by 3D power Doppler scan [Table 4].

Best 2D gray-scale ultrasound parameters for the detection of difficulty in placental separation and considerable

Table 2: Women who had difficulty in placental delivery, considerable intraoperative blood loss, and required emergency hysterectomies to stop bleeding compared with women who did not have difficulty in placental delivery or considerable blood or required hysterectomies

Variables	Women who had difficulty in placental delivery, considerable intraoperative blood loss, and required emergency hysterectomies	Women who did not have difficulty in placental delivery or considerable intraoperative blood loss or required emergency hysterectomies	P Significance
Age (years)			
Mean (SD)	30.3 (5.2)	30.9 (4.1)	0.13* (NS)
BMI, (kg/m ²)			
Mean (SD)	25.3 (3.2)	24.7 (2.9)	0.32* (NS)
Parity			
Median (range)	4 (1-6)	1 (1-2)	0.02** (S)
Number of previous cesarean section			
Median (range)	3 (1-4)	1 (1-2)	0.04** (S)
Gestational age at delivery (weeks)			
Mean (SD)	35.9 (1.7)	36.2 (1.4)	0.18* (NS)

*Analysis using independent Student's t-test, **Analysis using Mann–Whitney U-test. NS=Non-significant, S=Significant, BMI=Body mass index

Table 3: Two-dimensional gray-scale and three-dimensional power Doppler parameters in women who had difficulty in placental separation and considerable intraoperative blood loss compared with women who did not have difficulty in placental separation or considerable intraoperative blood loss

Variables	Women who had difficulty in placenta separation and considerable intraoperative blood loss (number=28) (%)	Women who did not have difficulty in placenta separation or considerable intraoperative blood loss (number=22) (%)	P Significance, RR (95% CI)
Two-dimensional gray-scale ultrasound findings			
Loss of retro-placental sonolucent space	26 (92.8)	7 (31.8)	0.03 (S), 2.9 (1.5-5.4)
Irregular retro-placental sonolucent area	25 (89.3)	5 (22.7)	0.01 (S), 3.0 (1.7-8.5)
Disruption of uterine serosa–bladder interface	18 (64.3)	2 (9.1)	<0.01 (S), 7.0 (1.8-27.2)
Exophytic mass invading bladder	8 (28.6)	0 (0)	<0.01 (S), 13.4 (0.8-22.1)
Abnormal placental lacunae	21 (75)	14 (63.6)	0.70 (NS), 0.39 (0.1-0.8)
Three dimensional power Doppler findings			
Disruption of uterine serosa–bladder interface	22 (78.6)	6 (27.3)	0.02 (S), 2.8 (1.4-5.8)
Numerous vessels invading serosa–bladder interface	22 (78.6)	6 (27.3)	0.02 (S), 2.8 (1.4-5.8)
Crowded vessels over peripheral sub-placental zone	25 (89.3)	6 (27.3)	0.02 (S), 3.2 (1.6-6.5)
Abnormal placental lacunae	17 (65.7)	15 (68.2)	0.70 (NS), 0.8 (0.5-1.3)

Data represented as number and percentage. Analysis using Chi-square test. NS=Non-significant, S=Significant. RR=Relative risk, CI=Confidence interval

Table 4: Two-dimensional gray-scale and three-dimensional power Doppler parameters in women who required emergency hysterectomies to stop bleeding compared with women who did not require hysterectomies

Variables	Women who required emergency hysterectomies (number=11) (%)	Women who did not require hysterectomies (number=39) (%)	P Significance, RR (95% CI)
Two-dimensional gray-scale ultrasound findings			
Loss of retro-placental sonolucent space	11 (100)	13 (33.3)	0.03 (S), 3 (1.9–4.6) 13 (33.3)
Irregular retro-placental sonolucent area	11 (100)	12 (30.8)	0.02 (S), 3.2 (1.9–4.6) 12 (30.8)
Disruption of uterine serosa–bladder interface	9 (81.8)	7 (17.9)	0.01 (S), 4.5 (2.2–33.7) 7 (17.9)
Exophytic mass invading bladder	4 (36.4)	2 (5.1)	0.02 (S), 7.1 (1.4–33.7) 2 (5.1)
Abnormal placental lacunae	8 (72.7)	26 (66.7)	0.80 (NS), 1.1 (0.7–1.6)
Three dimensional power Doppler findings			
Disruption of uterine serosa–bladder interface	10 (90.9)	8 (20.5)	<0.01 (S), 3.4 (1.8–6.3)
Numerous vessels invading serosa–bladder interface	6 (54.5)	24 (61.5)	0.80 (NS), 0.8 (0.4–1.6)
Crowded vessels over peripheral sub-placental zone	10 (90.9)	12 (30.8)	0.04 (S), 2.9 (1.7–4.9) 12 (30.8)
Abnormal placental lacunae	11 (28.2)	11 (28.2)	0.03 (S), 3.2 (1.8–5.5)

Data represented as number and percentage. Analysis using Chi-square test. NS=Non-significant, S=Significant, RR=Relative risk, CI=Confidence interval

intraoperative blood loss in the studied cases of MAP were abnormal placental lacunae (73.9% sensitivity), exophytic mass invading bladder (100% specificity and 100% positive predictive value [PPV]), and loss of retroplacental sonolucent space (74.2% NPV).

While best 3D power Doppler parameters were crowded vessels over peripheral sub-placental zone (79.6% sensitivity and 82.2% NPV) and disruption of uterine serosa–bladder interface (82.2% specificity and 79.7% PPV) [Table 5].

Best 2D gray-scale ultrasound parameters for the detection of hysterectomies in the studied cases of MAP were disruption of uterine serosa–bladder interface (81.8% sensitivity) and exophytic mass invading bladder (94.9% specificity, 66.7% PPV, and 84.1% NPV).

While best 3D power Doppler parameters for the detection of hysterectomies in the studied cases were disruption of uterine serosa–bladder interface (90.9% sensitivity, 68.8% specificity, and 47% PPV) and crowded vessels over peripheral sub-placental zone (93.2% NPV) [Table 6].

DISCUSSION

Hemorrhagic and surgical complications associated with MAP depend on the depth of placental invasion and involvement of adjacent structures.^[22]

MAP with bladder invasion is a serious condition, which necessitates proper antenatal diagnosis and appropriate management strategy.^[23]

Previous cesarean delivery and parity are the two known risk factors for MAP, and the incidence of MAP is increased concomitantly with increased cesarean section rates.^[3,24,25]

Prenatal diagnosis of MAP is crucial for proper counseling for possible surgical complications, multidisciplinary team care, and recruitment.^[3]

Table 5: Accuracy of two-dimensional gray-scale and three-dimensional power Doppler parameters in the prediction of difficult placental separation and considerable intraoperative blood loss

Variables	Sensitivity (%)	Specificity (%)	PPV (%)	NPV (%)
Two-dimensional gray-scale ultrasound findings				
Loss of retro-placental sonolucent space	70	59.3	64	74.2
Irregular retro-placental sonolucent area	72.6	63	65.5	71
Disruption of uterine serosa–bladder interface	43.5	88.9	76.9	64.9
Exophytic mass invading bladder	26.1	100	100	61.4
Abnormal placental lacunae	73.9	37	50	62.5
Three dimensional power Doppler findings				
Disruption of uterine serosa–bladder interface	77.2	82.2	79.7	79.9
Numerous vessels invading serosa–bladder interface	71.3	69.4	65.1	76.2
Crowded vessels over peripheral sub-placental zone	79.6	71.8	73	82.2
Abnormal placental lacunae	65.6	36.5	42.1	56.8

Data represented as percentage. PPV=Positive predictive value, NPV=Negative predictive value

Table 6: Accuracy of two-dimensional gray-scale and three-dimensional power Doppler parameters in the prediction of hysterectomies

Variables	Sensitivity (%)	Specificity (%)	PPV (%)	NPV (%)
Two-dimensional gray-scale ultrasound findings				
Loss of retro-placental sonolucent space	70	48.7	35.5	70
Irregular retro-placental sonolucent area	70	53.8	37.9	70
Disruption of uterine serosa–bladder interface	81.8	82.1	56.3	84.1
Exophytic mass invading bladder	63.4	94.9	66.7	84.1
Abnormal placental lacunae	72.7	33.3	23.5	81.3
Three dimensional power Doppler findings				
Disruption of uterine serosa–bladder interface	90.9	68.8	47	90.8
Numerous vessels invading serosa–bladder interface	90.9	60.5	40.3	92.2
Crowded vessels over peripheral sub-placental zone	90.9	61.1	41	93.2
Abnormal placental lacunae	62.7	32.9	21.2	82.4

Data represented as percentage. PPV=Positive predictive value, NPV=Negative predictive value

Despite its cost and unavailability in many centers, MRI should be reserved for cases with inconclusive sonographic findings.^[13,15,17]

Recently, 3D ultrasound and 3D Power Doppler were introduced for the detection of MAP. Using 3D power Doppler, the vascularization index, flow index (FI), and

vascularization FI can be used for the detection of MAP using the VOCAL method in the ROI.^[26,27]

Fifty women \geq 28 weeks' gestation with expected MAP (placenta previa anterior covering scar of previous cesarean section) were studied and scanned with 2D ultrasound and 3D power Doppler to confirm the diagnosis of MAP. Intraoperative findings and histopathology results of removed uteri were compared with preoperative sonographic findings to detect the accuracy of 2D gray-scale and 3D power Doppler ultrasound parameters in the diagnosis of MAP. Forty-six of studied women were delivered at 35 weeks by planned cesarean section, whereas 4 women were delivered at 33 weeks because of ante-partum hemorrhage.

Fifty-six percentage (28/50) of the studied women had difficulty in placental separation, considerable intraoperative blood loss, and received intraoperative blood transfusion. In this study, parity and number of previous cesarean sections were significantly high among women, who had difficulty in placental delivery, who had considerable intraoperative blood loss, and who required emergency hysterectomies to control bleeding. Wright *et al.* found that 41.7% of women with placenta accreta had \geq 5000 ml blood loss.^[28]

Although Wright *et al.* concluded that there was no significant relation among parity, number of previous cesarean deliveries, degree of placental invasion, and massive blood loss, Tikkanen *et al.* found that the risk factors of placenta accreta include parity, cesarean section, and placenta previa.^[28,29]

Guleria *et al.* concluded that risk factors of abnormal invasive placentation (AIP) were placenta previa and previous cesarean delivery and Thia *et al.* concluded that depth of invasion in MAP is increased with multiple previous surgery or excessive curettage or infection causing defective decidua basalis.^[30,31]

D'Antonio *et al.* concluded that the incidence of AIP increased in the past decades as a consequence of increasing cesarean section rates and ultrasound has 91% sensitivity and 97% specificity in the prediction of all forms of AIP.^[16]

Bilateral internal iliac artery ligation was needed in 28% of studied women, intrauterine compression balloon with placenta bed sutures was needed in 6% of studied women, and cesarean hysterectomies were done in 22% of studied women.

Warshak *et al.* concluded that antenatal detection of placenta accreta was associated with significant decrease in maternal hemorrhage, also, Tikkanen *et al.* concluded that antenatal diagnosis of placenta accreta may significantly

reduce peripartum blood loss and Chantraine *et al.* concluded that antenatal diagnosis of AIP reduces morbidity and undiagnosed cases of AIP led to more emergency hysterectomies.^[29,32,33]

Eller *et al.* concluded that planned cesarean hysterectomy and preoperative ureteric stents were associated with reduced maternal morbidity in MAP.^[34]

In this study, best 2D gray-scale ultrasound parameters for the detection of difficulty in placental separation and considerable intraoperative blood loss were abnormal placental lacunae (73.9% sensitivity), exophytic mass invading bladder (100% specificity and 100% PPV), and loss of retroplacental sonolucent zone (74.2% NPV). In addition, best 2D gray-scale ultrasound parameters for the detection of emergency hysterectomies in the studied cases were disruption of hyperechoic uterine serosa–bladder interface (81.8% sensitivity) and exophytic mass invading bladder (94.9% specificity, 66.7% PPV, and 84.1% NPV).

Dwyer *et al.* studied 32 women to compare the accuracy of trans-abdominal ultrasound and MRI for the diagnosis of placenta accrete. They found that ultrasound identified placenta accreta with 93% sensitivity and ruled out placenta accreta with 71% specificity, whereas MRI identified placenta accreta with 80% sensitivity and ruled out placenta accreta with 65% specificity.^[15]

Warshak *et al.* found that ultrasound accurately diagnosed MAP with 77% sensitivity and ruled out MAP with 96% specificity and concluded that MRI may be helpful in the diagnosis of MAP in cases with inconclusive ultrasound findings.^[13]

Comstock *et al.* concluded that multiple vascular spaces inside placenta (placental lacunae) was the most diagnostic sign for placenta accrete with high PPV.^[35]

In addition, they concluded that obliteration of retroplacental is not a reliable sign for the diagnosis of placenta accreta, since the spaces may normally absent and they recommended the use of color Doppler to identify placental sinuses crossing the uterine wall to bladder.^[35]

Wong *et al.* concluded that loss of placental–uterine interface and presence of abnormal vessels crossing this interface were the most specific criteria to diagnose the MAP using 2D gray-ultrasound scan.^[36]

Wong *et al.* found that the major risk of placenta accreta is severe hemorrhage when the placenta separated at delivery. They concluded that the extent of myometrial involvement and the vascularity could be detected by the observation

of placental–uterine wall interface disruption and the vessels crossing the interface disruption sites. In addition, they concluded that such assessment results in strategic planning of management of the placenta at delivery with favorable pregnancy outcomes.^[36]

Wong *et al.* concluded that the sonographic criteria useful for the assessment of the lateral placental/myometrial involvement in MAP were obliteration of retroplacental clear space, increased sub-placental vascularity, placental-tissue interface disruption, and vessels crossing the interface disruption site.^[37]

In addition, they also concluded that the useful sonographic criteria for the assessment of the depth of placental/myometrial involvement were bladder serosa–uterine wall interface hyper-vascularity, vessels extending from placenta to bladder, placental-tissue interface disruption, and vessels crossing placental-tissue interface disruption.^[37]

In this study, best 3D power Doppler parameters for the detection of difficulty in placental separation and considerable intraoperative blood loss in studied cases were crowded vessels over peripheral sub-placental zone (79.6% sensitivity and 82.2% NPV) and disruption of hyperechoic serosa–bladder interface (82.2% specificity and 79.7% PPV). Best 3D power Doppler parameters for the detection of emergency hysterectomies in the studied cases were disruption of uterine serosa–bladder interface (90.9% sensitivity, 68.8% specificity, and 47% PPV) and crowded vessels over peripheral sub-placental zone (93.2% NPV).

Negrini *et al.* concluded that the use of 3D power Doppler vascular indices at different points of the placenta between 22 and 34 weeks of gestation showed significant difference between the vascular indices obtained with a 3D power Doppler at different points of the placenta and the only limitation of 3D power Doppler analysis was the low reproducibility.^[27]

Moodley *et al.* studied 30 cases with placenta previa and they found that 2 (66.6%) cases required cesarean hysterectomy and 1 (33.3%) case required internal iliac ligation to control bleeding. They concluded that color flow Doppler was more specific in the diagnosis of MAP than MRI with 95% NPV.^[17]

Zhang *et al.* found that color Doppler had 77.3% sensitivity, 98.4% specificity, 85.0% PPV, and 97.4% NPV in the diagnosis of placenta increta. Zhang *et al.* concluded that prenatal color Doppler ultrasound has a high sensitivity and specificity for the identification of placenta previa increta.^[14]

Shi *et al.* found that the most prominent gray-scale sign to diagnose placenta accreta was dilated vessels extending

from placenta to myometrium, and the most prominent color Doppler diagnostic sign was the presence of abnormal vessels connecting placenta to bladder.^[38]

Shih *et al.* found that numerous vessels by 3D power Doppler was the best single diagnostic sign of placenta accreta, with 97% sensitivity and they concluded that 3D power Doppler is a useful tool for the diagnosis of MAP.^[39]

Chou *et al.* found that color Doppler had 82.4% sensitivity, 96.8% specificity, 87.5% and 95.3% positive and NPVs, respectively.^[12]

Chou *et al.* in another study found a strong association between bladder invasion in MAP and 3D power Doppler findings, particularly uterine–bladder interface hyper-vascularization and large rosette of varicosities in the area of bladder base.^[22]

Chou *et al.* concluded that 3D ultrasound can be used as an adjunctive tool with 2D ultrasound to identify the extent of invasion in the cases of MAP.^[22] Advantages of 3D ultrasound are (1) Multiplanes image display (sagittal, coronal and axial planes at the same time), (2) Viewing planes of vasculature can be manipulated to identify vessels invading bladder.^[21]

In addition, Cali *et al.* found that irregular tortuous vessels affecting entire placenta and uterine serosa–bladder interface were the diagnostic signs of MAP by 3D power Doppler.^[40]

Cali *et al.* studied one hundred and eighty-seven women with placenta previa and history of uterine surgery to evaluate the diagnostic accuracy of 2D gray-scale, color Doppler, and 3D power Doppler sonography in diagnosing MAP.^[40]

Cali *et al.* found that irregular intra-placental vascularization with tortuous confluent vessels affecting the entire width of placenta and hypervascularity of uterine serosa–bladder interface were the diagnostic signs of MAP by 3D power Doppler. Cali *et al.* concluded that 3D power Doppler was an important diagnostic tool to differentiate between placenta accreta and percreta.^[40]

The strength of the study is coming from proper statistical analysis to detect the accuracy of gray-scale and 3D power Doppler ultrasound parameters in the diagnosis of MAP and women refused to participate (2 women) was the only limitation faced during conduction of this study.

Adherence to hospital protocols and proper prenatal diagnosis of the cases of MAP are essential for recruitment of multidisciplinary care team, to prepare patients and health providers for possible intraoperative complications.

CONCLUSION

3D power Doppler is a useful complementary tool to 2D gray-scale ultrasound for prenatal diagnosis of MAP. Crowded vessels over peripheral sub-placental zone and disruption of uterine serosa–bladder interface were the best 3D power Doppler parameters for the detection of difficult placental separation, considerable intraoperative blood loss, and emergency hysterectomies in studied cases.

Acknowledgment

The authors are grateful to all women who agreed to participate in this study.

Financial support and sponsorship

Nil.


Conflicts of interest

There are no conflicts of interest.

REFERENCES

- Wong HS, Zuccollo J, Strand L, Tait J, Pringle KC. The use of ultrasound in assessing the extent of myometrial involvement in partial placenta accreta. *Ultrasound Obstet Gynecol* 2007;30:228-30.
- Abuhamad A. Morbidly adherent placenta. *Semin Perinatol* 2013;37:359-64.
- Abdel Moniem AM, Ibrahim A, Akl SA, Aboul-Enen L, Abdelazim IA. Accuracy of three-dimensional multislice view Doppler in diagnosis of morbid adherent placenta. *J Turk Ger Gynecol Assoc* 2015;16:126-36.
- Silver RM, Landon MB, Rouse DJ, Leveno KJ, Spong CY, Thom EA, et al. Maternal morbidity associated with multiple repeat cesarean deliveries. *Obstet Gynecol* 2006;107:1226-32.
- Wortman AC, Alexander JM. Placenta accreta, increta, and percreta. *Obstet Gynecol Clin North Am* 2013;40:137-54.
- Rao KP, Belogolovkin V, Yankowitz J, Spinnato JA 2nd. Abnormal placentation: Evidence-based diagnosis and management of placenta previa, placenta accreta, and vasa previa. *Obstet Gynecol Surv* 2012;67:503-19.
- Khong TY. The pathology of placenta accreta, a worldwide epidemic. *J Clin Pathol* 2008;61:1243-6.
- Moniem AM, Abdelrazak KM, Hussain M, Awadalla AM, Abdelazim IA. Outcomes and accuracy of 2D grayscale ultrasound scan in prenatal diagnosis of morbid adherent placenta. *Gynecol Obstet Res Open J* 2015;2:62-8.
- Getahun D, Oyelese Y, Salihu HM, Ananth CV. Previous cesarean delivery and risks of placenta previa and placental abruption. *Obstet Gynecol* 2006;107:771-8.
- Oyelese Y, Smulian JC. Placenta previa, placenta accreta, and vasa previa. *Obstet Gynecol* 2006;107:927-41.
- Eshkoli T, Weintraub AY, Sergienko R, Sheiner E. Placenta accreta: Risk factors, perinatal outcomes, and consequences for subsequent births. *Am J Obstet Gynecol* 2013;208:219.e1-7.
- Chou MM, Ho ES, Lee YH. Prenatal diagnosis of placenta previa accreta by transabdominal color Doppler ultrasound. *Ultrasound Obstet Gynecol* 2000;15:28-35.
- Warshak CR, Eskander R, Hull AD, Scioscia AL, Mattrey RF, Benirschke K, et al. Accuracy of ultrasonography and magnetic resonance imaging in the diagnosis of placenta accreta. *Obstet Gynecol* 2006;108 (3 Pt 1):573-81.
- Zhang L, Li P, He GL, Liu XH, Yang TZ, Luo H, et al. Value of prenatal diagnosis of placenta previa with placenta increta by transabdominal color Doppler ultrasound. *Zhonghua Fu Chan Ke Za Zhi* 2006;41:799-802.
- Dwyer BK, Belogolovkin V, Tran L, Rao A, Carroll I, Barth R, et al. Prenatal diagnosis of placenta accreta: Sonography or magnetic resonance imaging? *J Ultrasound Med* 2008;27:1275-81.
- D'Antonio F, Bhide A. Ultrasound in placental disorders. *Best Pract Res Clin Obstet Gynaecol* 2014;28:429-42.
- Moodley J, Ngambu NF, Corr P. Imaging techniques to identify morbidly adherent placenta praevia: A prospective study. *J Obstet Gynaecol* 2004;24:742-4.
- Al Obaidly S, Kurjak A. Prenatal diagnosis of morbidly adherent placenta with 2D ultrasonography, 3D color power Doppler and magnetic resonance imaging. *Donald Sch J Ultrasound Obstet Gynecol* 2010;4:199-204.
- Comstock CH, Lee W, Vettraino IM, Bronsteen RA. The early sonographic appearance of placenta accreta. *J Ultrasound Med* 2003;22:19-23.
- Al-Zirqi I, Stray-Pedersen B, Forsén L, Daltveit AK, Vangen S; NUR Group. Validation study of uterine rupture registration in the Medical Birth Registry of Norway. *Acta Obstet Gynecol Scand* 2013;92:1086-93.
- Stafford I, Dildy GA, Clark SL, Belfort MA. Visually estimated and calculated blood loss in vaginal and cesarean delivery. *Am J Obstet Gynecol* 2008;199:519.e1-7.
- Chou MM, Chen WC, Tseng JJ, Chen YF, Yeh TT, Ho ES. Prenatal detection of bladder wall involvement in invasive placentation with sequential two-dimensional and adjunctive three-dimensional ultrasonography. *Taiwan J Obstet Gynecol* 2009;48:38-45.
- Comstock CH. Antenatal diagnosis of placenta accreta: A review. *Ultrasound Obstet Gynecol* 2005;26:89-96.
- Bencaiova G, Burkhardt T, Beinder E. Abnormal placental invasion experience at 1 center. *J Reprod Med* 2007;52:709-14.
- Grobman WA, Gersnoviez R, Landon MB, Spong CY, Leveno KJ, Rouse DJ, et al. Pregnancy outcomes for women with placenta previa in relation to the number of prior cesarean deliveries. *Obstet Gynecol* 2007;110:1249-55.
- Bauer ST, Bonanno C. Abnormal placentation. *Semin Perinatol* 2009;33:88-96.
- Negrini R, de Silva Bussamra LC, da Silva Valladao de Freitas L, Araujo Júnior E, Piatto S, Nardoza LM, et al. Assessment of placental blood flow between 22 and 34 weeks of gestation by 3D-sonography power Doppler vascular indices. *Arch Gynecol Obstet* 2011;284:53-7.
- Wright JD, Pri-Paz S, Herzog TJ, Shah M, Bonanno C, Lewin SN, et al. Predictors of massive blood loss in women with placenta accreta. *Am J Obstet Gynecol* 2011;205:38.e1-6.
- Tikkanen M, Paavonen J, Loukovaara M, Stefanovic V. Antenatal diagnosis of placenta accreta leads to reduced blood loss. *Acta Obstet Gynecol Scand* 2011;90:1140-6.
- Guleria K, Gupta B, Agarwal S, Suneja A, Vaid N, Jain S. Abnormally invasive placenta: Changing trends in diagnosis and management. *Acta Obstet Gynecol Scand* 2013;92:461-4.
- Thia EW, Lee SL, Tan HK, Tan LK. Ultrasonographical features of morbidly-adherent placentas. *Singapore Med J* 2007;48:799-802.
- Warshak CR, Ramos GA, Eskander R, Benirschke K, Saenz CC, Kelly TF, et al. Effect of predelivery diagnosis in 99 consecutive cases of placenta accreta. *Obstet Gynecol* 2010;115:65-9.
- Chantraine F, Braun T, Gonser M, Henrich W, Tutschek B. Prenatal diagnosis of abnormally invasive placenta reduces maternal peripartum hemorrhage and morbidity. *Acta Obstet Gynecol Scand* 2013;92:439-44.
- Eller AG, Porter TF, Soisson P, Silver RM. Optimal management strategies for placenta accreta. *BJOG* 2009;116:648-54.
- Comstock CH, Love JJ Jr, Bronsteen RA, Lee W, Vettraino IM, Huang RR, et al. Sonographic detection of placenta accreta in the second and third trimesters of pregnancy. *Am J Obstet Gynecol* 2004;190:1135-40.

36. Wong HS, Zuccollo J, Tait J, Pringle K. Antenatal topographical assessment of placenta accreta with ultrasound. *Aust N Z J Obstet Gynaecol* 2008;48:421-3.
37. Wong HS, Cheung YK, Williams E. Antenatal ultrasound assessment of placental/myometrial involvement in morbidly adherent placenta. *Aust N Z J Obstet Gynaecol* 2012;52:67-72.
38. Shi H, Pi P, Ding Y. Diagnosis of placenta previa accreta by two dimensional ultrasonography and color Doppler in patients with cesarean section. *Zhong Nan Da Xue Xue Bao Yi Xue Ban* 2012;37:939-43.
39. Shih JC, Palacios Jaraquemada JM, Su YN, Shyu MK, Lin CH, Lin SY, et al. Role of three-dimensional power Doppler in the antenatal diagnosis of placenta accreta: Comparison with gray-scale and color Doppler techniques. *Ultrasound Obstet Gynecol* 2009;33:193-203.
40. Cali G, Giambanco L, Puccio G, Forlani F. Morbidly adherent placenta: Evaluation of ultrasound diagnostic criteria and differentiation of placenta accreta from percreta. *Ultrasound Obstet Gynecol* 2013;41:406-12.



Staying in touch with the journal

1) Table of Contents (TOC) email alert

Receive an email alert containing the TOC when a new complete issue of the journal is made available online. To register for TOC alerts go to www.jbcrs.org/signup.asp.

2) RSS feeds

Really Simple Syndication (RSS) helps you to get alerts on new publication right on your desktop without going to the journal's website. You need a software (e.g. RSSReader, Feed Demon, FeedReader, My Yahoo!, NewsGator and NewzCrawler) to get advantage of this tool. RSS feeds can also be read through FireFox or Microsoft Outlook 2007. Once any of these small (and mostly free) software is installed, add www.jbcrs.org/rssfeed.asp as one of the feeds.

