

A Rare Case of Peritoneal Spread of Benign Struma Ovarii with Thyrotoxicosis

Abhijeet Ingle*, Vijaya Gattu, Suhela Rachakonda, Sachin Subhash Marda

Yashoda Hospital, Hyderabad, TS, India

Received date: May 30, 2017; Accepted date: March 16, 2018; Published date: March 20, 2018.

Abstract

Background: Struma ovarii is a highly specialized form of mature ovarian teratoma consisting of thyroid tissue and exhibiting all the histological features of the thyroid gland. Malignant transformation of thyroid tissue in struma ovarii and metastasis are extremely uncommon. In rare cases, benign thyroid tissue may spread to the peritoneal cavity, and pathologic examination of the peritoneal implants shows multiple nodules of varying sizes of mature thyroid tissue similar to struma ovarii.

Summary: We report a 30-year-old woman with struma ovarii complicated by peritoneal dissemination with thyrotoxicosis. After surgical resection of the struma ovarii and peritoneal implants the patient became euthyroid.

Keywords: Struma ovarii, Highly differentiated follicular carcinoma of ovarian origin, Peritoneal dissemination, Radioiodine ablation, Extra-ovarian tumour.

Introduction

Twenty percent of ovarian tumours are teratomas, and up to 20% of teratomas contain thyroid tissue. Struma ovarii consisting of at least 50% of thyroid tissue [1] is less common and accounts for 1-4% of benign ovarian teratomas. Bilateral struma ovarii is very rare and has not been reported frequently [2]. Struma ovarii usually shows up as a pelvic mass and presents as pseudo-Meigs' syndrome in about 5% of cases [3]. However, preoperative diagnosis of struma ovarii is rarely reported and may occur in patients with symptoms of hyperthyroidism but this association is observed in less than 5% of cases [4].

Malignant transformation of thyroid tissue in struma ovarii and metastasis is uncommon. Benign thyroid tissue may spread to the peritoneal cavity in rare cases, and pathologic examination of the peritoneal implants shows multiple nodules of varying sizes of mature thyroid tissue similar to struma ovarii [5]. Because of its harmless histological appearance, this form of follicular carcinoma cannot be diagnosed until the neoplasm spreads beyond the ovary thus showing evidence of aggressive behaviour [6]. The differential diagnosis of peritoneal dissemination of struma includes typical thyroid carcinoma metastatic to the ovary, which has also been reported [7].

Histological features of thyroid carcinoma are found in ~ 5% struma ovarii (referred to as malignant struma ovarii) [2]. The nuclear features of papillary carcinoma are usually used as the criteria for diagnosis of malignant struma ovarii, and most cases reported are papillary carcinoma [8,9]. In recent large studies on malignant struma ovarii, the clinical behaviour was difficult to predict based on tumor histomorphology alone [10]. Immunohistochemical staining with HBME-1 (Hector Battifora mesothelial [cell]-1) and galectin-3, often expressed in papillary thyroid carcinoma, can also help to confirm the diagnosis [11].

Case Report

Here we report a 30-year-old female patient G0 P2 L2A0 who was evaluated at an outside institution for left ovarian mass. Then she underwent laparoscopic left oophorectomy, and diagnosed as proliferative struma ovarii with nuclear atypia, 2 years back. The histological report was available and reviewed. Then she developed lower abdominal pain (right side) since 4-5 months, associated with weight loss.

Chest X-ray was normal and ultrasound abdomen showed multiple space occupying lesions (SOLs) in pelvis

Corresponding Author:

Abhijeet I, Department of Consultant Histopathologist, Yashoda Hospital, Hyderabad, India, E-mail: abhiingle@yahoo.co.in

DOI:

10.4103/2278-960X.194513

This is an open access article distributed under the terms of the Creative Commons Attribution-NonCommercial-ShareAlike 3.0 License, which allows others to remix, tweak, and build upon the work non-commercially, as long as the author is credited and the new creations are licensed under the identical terms.

For reprints contact: editor@jbcrs.org

Copyright: © 2017 Abhijeet I, et al. This is an open-access article distributed under the terms of the Creative Commons Attribution License, which permits unrestricted use, distribution, and reproduction in any medium, provided the original author and source are credited.

and lower abdomen bilaterally-suggestive of metastatic nodes and ascites. Thyroid profile showed raised T3, T4 and low TSH

PET CT scan of the abdomen and pelvis demonstrated multiple peritoneal deposits scattered in entire abdominal cavity with a max standardized uptake value of 6.7 (Figures 1 and 2).

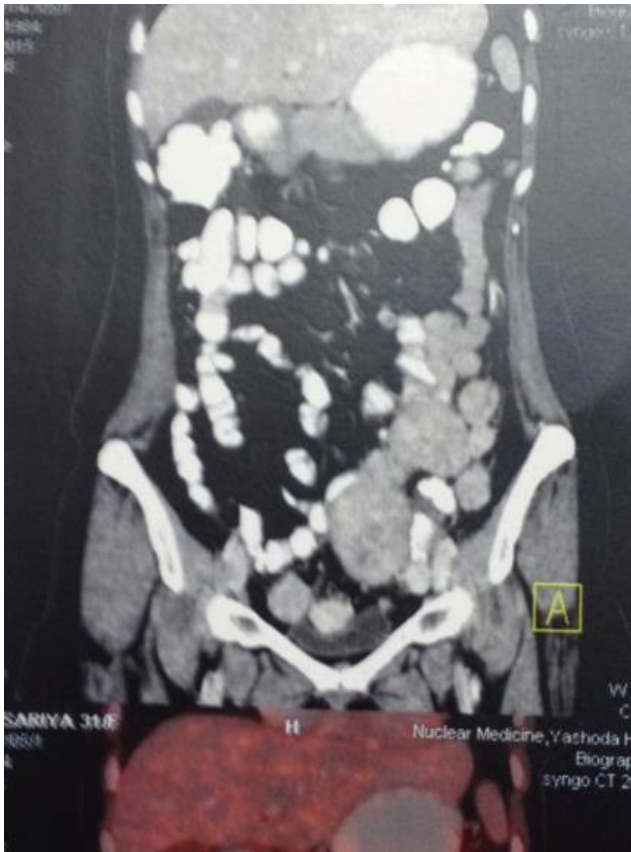

Figure 1: PET CT scan of the abdomen demonstrated multiple peritoneal deposits scattered in entire abdominal cavity with a max standardized uptake value of 6.7.

Ultrasound guided biopsy from one of the peritoneal lesions and ascitic fluid cytology revealed atypical cells. Then she underwent radical hysterectomy with right salpingo-oophorectomy, Total omentectomy, Distal small bowel tumour resection and end to end Anastomosis, resection of anterior wall deposit, Extensive total peritonectomy, excision of mesenteric and small bowel deposit and total thyroidectomy. The specimens were submitted for histopathological examination.

Multiple grey white to brownish nodules were seen scattered all over the surface of uterus, right ovary and fallopian tube, largest nodule measuring 1.5 × 1 × 1.5 cms. (Figure 3). Omentum showed multiple grey white to brownish nodules, largest nodule measuring 3.0 × 2.5 × 2.5 cms. (Figure 4). Similar deposits were observed on small bowel, anterior abdominal wall, Pouch of Douglas (POD), paracolic gutter, and diaphragmatic peritoneum (Figures 5 and 6). Grossly thyroidectomy specimen was unremarkable.

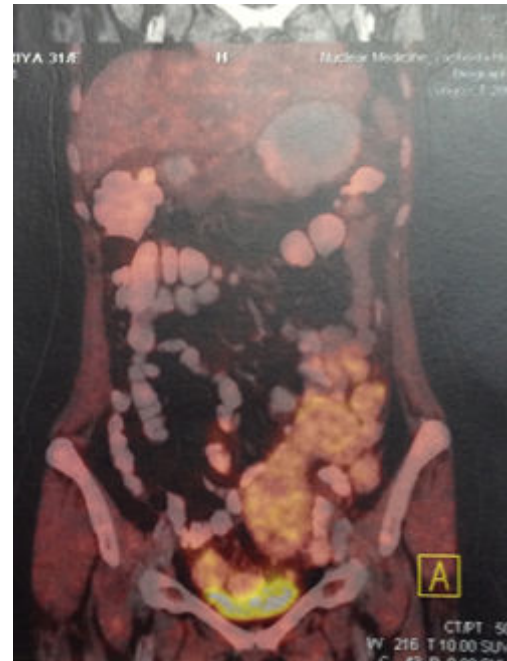

Figure 2: PET CT scan of the pelvis demonstrated multiple peritoneal deposits scattered in entire abdominal cavity with a max standardized uptake value of 6.7.

Histopathological examination from the slides reviewed from left ovarian mass showed cyst wall lined by skin and skin adnexal structures, keratinous material and calcific debris. Also showed closely packed thyroid follicles containing thin colloid, the lining cells show mild nucleomegaly, focal nuclear overlapping, and nuclear clearing at most places. Occasional intranuclear grooves are seen; hence, diagnosed as proliferative struma ovarii with nuclear atypia (Figure 7).

Histopathological examination from the slides reviewed from left ovarian mass showed cyst wall lined by skin and skin adnexal structures, keratinous material and calcific debris.

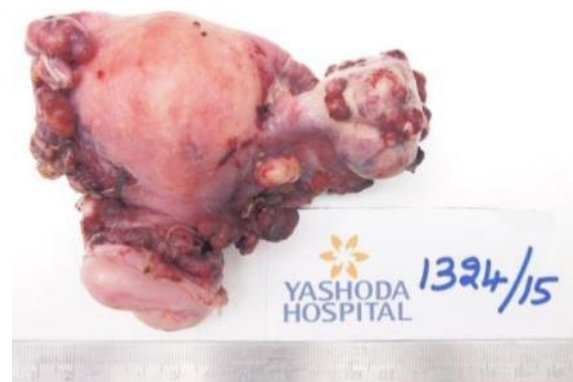

Figure 3: Multiple grey white to brownish nodules were seen scattered all over the surface of uterus, right ovary and fallopian tube, largest nodule measuring 1.5 × 1 × 1.5 cm.

Histopathological examination from representative areas from above mentioned organs revealed encapsulated nodular tumours composed of closely packed micro follicles, lined by cuboidal cells having round to slightly irregular nuclei, mild anisonucleosis seen. Focally chromatin clearing and occasional intranuclear grooves seen.

The unequivocal features of papillary carcinoma were not seen. Diagnosis of peritoneal spread of benign struma ovarii was made (Metastatic highly differentiated thyroid carcinoma) (Figures 8 and 9). However sections from urinary bladder and thyroidectomy specimen were unremarkable.

Immunohistochemistry performed on multiple nodules -CK¹⁹ was focally positive and p⁵³ was negative.

Discussion

Roth et al. described in detail the cases of peritoneal implantation or dissemination of thyroid tissues.

They also proposed considering highly differentiated follicular carcinoma of ovarian origin as a new entity, which resembles thyroid goiter but causes metastasis.

In this context, some cases in which peritoneal dissemination was found at the time of surgery for ovarian tumor seems to be malignant struma ovarii, and the term 'peritoneal strumosis' should be used only in cases in which the primary ovarian tumor is purely benign [6].

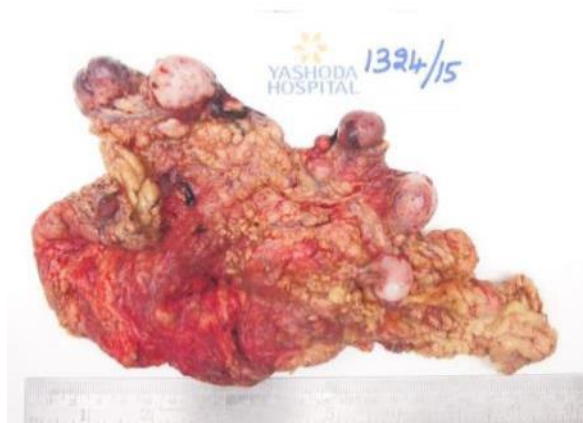

Figure 4: Omentum showed multiple grey white to brownish nodules, largest nodule measuring 3.0 × 2.5 × 2.5 cms.

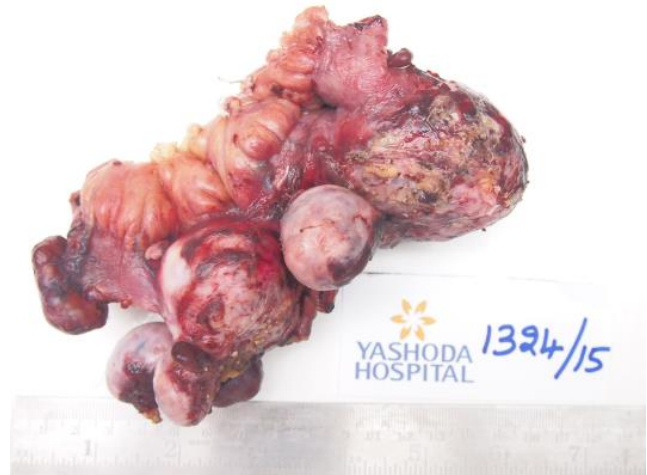

Figure 5: Deposits were observed on small bowel, anterior abdominal wall.

Our patient presented with recurrence and peritoneal spread of a benign struma ovarii 2 years after the first diagnosis.

A review of 39 patients with malignant struma ovarii showed only 9 patients (23%) with metastasis.

The predominant sites were adjacent pelvic structures including the contralateral ovary, but some patients had distant metastases to the lungs, bone, liver, and brain [12].

McGill et al. performed a review on 40 patients with struma ovarii and concluded also that the recommended treatment of metastatic struma ovarii should contain total thyroidectomy in conjunction with radioiodine scanning and radioiodine ablation [13]; another two case reports came to similar conclusions [14,15].

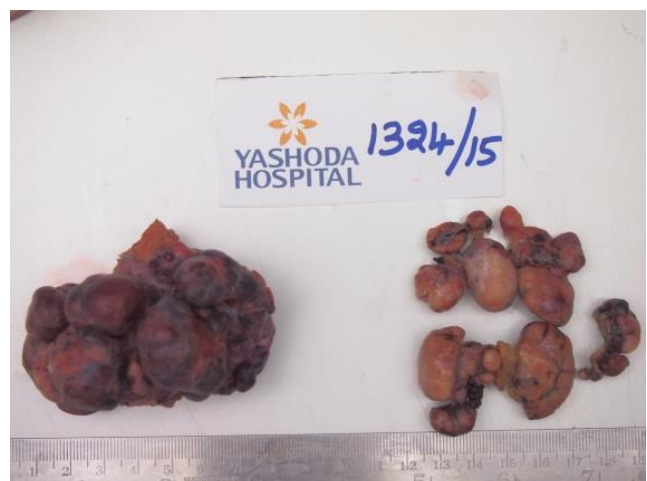

Figure 6: Deposits were observed on pouch of Douglas (POD), paracolic gutter, and diaphragmatic peritoneum.

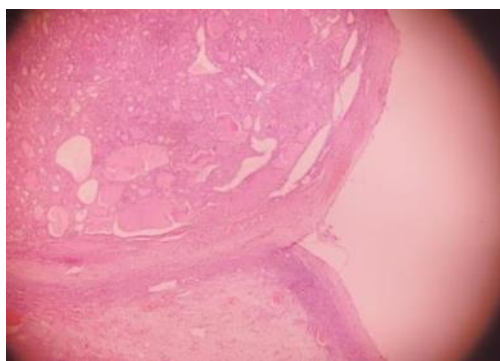


Figure 7: Intranuclear grooves are seen as proliferative struma ovarii with nuclear atypia.

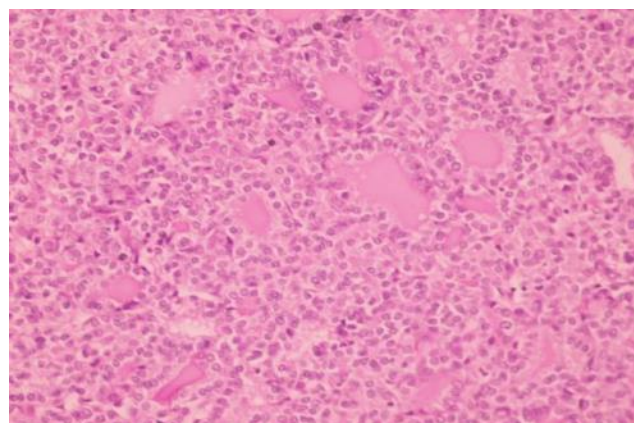
Follow up may include the use of thyroglobulin as a tumour marker, and diagnostic radioiodine scans may be performed to screen for residual or recurrent disease [16]. Repeat ablative radioiodine treatment may still have a curative potential or at least can provide extended disease free survival. Recombinant human TSH (rhTSH) is occasionally used before ¹³¹I administration to achieve a concentration of ¹³¹I activity in the tumour high enough for a significant cytotoxic effect, because ¹³¹I uptake by most of thyroid carcinomas is quite low in absence of high levels of endogenous TSH [17,18]. Zekri et al. had described a patient with struma ovarii that was initially diagnosed as benign and presented 10 years later with distant metastases [19].

Conclusion

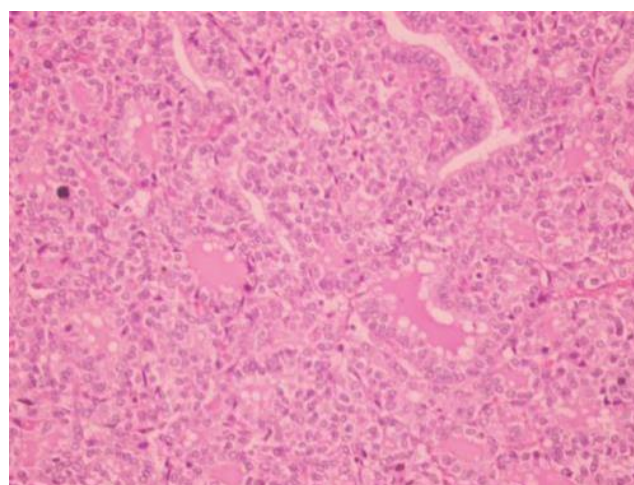
In our case the diagnosis at the time of first laparoscopic surgery (left oophorectomy) was benign struma ovarii with nuclear atypia. There was no evidence of malignancy in all the slides reviewed. Final diagnosis at the time of second surgery from peritoneal implants also showed benign thyroid tissue with occasional nuclear grooves. Unequivocal features of papillary thyroid carcinoma were not seen. Hence we consider our case as a 'pure' peritoneal strumosis.

Patient with benign metastatic struma ovarii (also known as highly differentiated follicular carcinoma of ovarian origin - HDFCO) may affectively be treated with local resection of the extra ovarian tumour and subsequent thyroidectomy followed by radioactive iodine ablation.

If preservation of fertility is desired and the carcinoma is limited to the ovary, unilateral salpingo-oophorectomy or strumectomy is suggested; otherwise, total abdominal hysterectomy and bilateral salpingo-oophorectomy are typically performed. Sequential thyroglobulin measurements along with total-body scintiscanning with ¹³¹I follow-up are recommended if recurrence is suspected. Thyroid-type carcinomas arising in struma ovarii, especially the newly recognized entity-HDFCO have a favourable prognosis.



Figures 8: Metastatic highly differentiated thyroid carcinoma.



Figures 9: Diagnosis of peritoneal spread of benign struma ovarii.

If preservation of fertility is desired and the carcinoma is limited to the ovary, unilateral salpingo-oophorectomy or strumectomy is suggested; otherwise, total abdominal hysterectomy and bilateral salpingo-oophorectomy are typically performed. Sequential thyroglobulin measurements along with total-body scintiscanning with ¹³¹I follow-up are recommended if recurrence is suspected. Thyroid-type carcinomas arising in struma ovarii, especially the newly recognized entity-HDFCO have a favourable prognosis.

References

1. Yassa L, Sadow P, Marqusee E. Malignant struma ovarii. *Nat Clin Pract Endocrinol Metab.* 2008;4:469-472.
2. Ayhan A, Yanik F, Tuncer R, et al. Struma ovarii. *Int J Gynaecol Obstet.* 1993;42:143-146.
3. Huh Julie J, Montz FJ, Bristow Robert E. Stuma ovarii associated with pseudo -Meigs'syndrome and elevated serum CA 125. *Gynecol Oncol.* 2002; 6:231-234.
4. Kim JC, Kim SS, Park JY. MR findings of struma ovarii. *Clin Imaging* 2000;24:28-33.
5. Kim D, Cho HC, Park JW, et al. Struma Ovarii and Peritoneal Strumosis with Thyrotoxicosis. *Thyroid.* 2009;19(3):305-308.
6. Roth LM, Karseladze AI. Highly differentiated follicular carcinoma arising from struma ovarii: a report of 3 cases, a review of the

- literature, and a reassessment of so-called peritoneal strumosis. *Int J Gynecol Pathol.* 2008; 27:213-222.
7. Brogioni S, Viacava P, Tomisti L, et al. A special case of bilateral ovarian metastases in a woman with papillary carcinoma of the thyroid. *Exp Clin Endocrinol.* 2007;115:397-400.
 8. Crum CP, Lee KR, Medeiros F. et al. Germ cell tumours of the ovary. In *Diagnostic Gynecologic and Obstetric Pathology*, Philadelphia, Elsevier Saunders. 2006;920-921.
 9. Devaney K, Snyder R, Norris HJ, et al. Proliferative and histologically malignant struma ovarii: a clinicopathologic study of 54 cases. *Int J Gynecol Pathol.* 1993;12:333-343.
 10. Shaco-Levy R. Malignant struma ovarii: a blinded study of 86 cases assessing which histologic features correlate with aggressive clinical behavior. *Arch Pathol Lab Med.* 2012;136(2):172.
 11. Nakamura N, Erickson LA, Jin L, et al. Immunohistochemical separation of follicular variant of papillary thyroid carcinoma from follicular adenoma. *Endocrine Pathol.* 2006;17:213-223.
 12. Makani S, Kim W, Gaba A. Struma ovarii with a focus of papillary thyroid cancer: a case report and review of the literature. *Gynecol Oncol.* 2004;94:835-839.
 13. McGill JF, Sturgeon C, Angelos P. Metastatic struma ovarii treated with total thyroidectomy and radioiodine ablation. *Endocrine Practice.* 2009;15(2):167-73.
 14. Zekri JM, Manifold IH, Wadsley JC. Metastatic struma ovarii: late presentation, unusual features and multiple radioactive iodine treatments. *Clin Oncol.* 2006;18(10):768-72.
 15. Brogsitter C, Wonsak A, Würl K, et al. Peritoneal strumosis. *Eur J Nucl Med Mol Imaging* 2004;31(7):1057.
 16. Dardik RB, Dardik M, Westra W, et al. Malignant struma ovarii: Two case reports and a review of the literature. *Gynecol Oncol.* 1999;73:447-451.
 17. Rotman-Pikielny P, Reynolds JC, Barker WC, et al. Recombinant human thyrotropin for the diagnosis and treatment of a highly functional metastatic struma ovarii. *J Clin Endocrinol Metab* 2000;85:237-244.
 18. Papanikolaou C, Fortounis K, Biba K, et al. Struma Ovarii. *The Internet J Surg.* 2007; 9(2): 7.
 19. Zekri JM, Manifold IH, Wadsley JC. Metastatic struma ovarii: late presentation, unusual features and multiple radioactive iodine treatments. *Clin Oncol.* 2006;18(10):768-72.